

# AVIAN LAPAROSCOPY AS A FIELD TECHNIQUE FOR SEXING BIRDS AND AN ASSESSMENT OF ITS EFFECTS ON WILD BIRDS

HEINZ RICHNER

*Institut de Zoologie et d'Ecologie animale  
Université de Lausanne  
1015 Lausanne, Switzerland*

**Abstract.**—Three hundred and four Carrion Crows (*Corvus corone corone*) were sexed in both field and laboratory using laparoscopy. A Hopkins diagnostic arthroscope was used for observing the gonads of the birds. Laparoscopy, unknown to most professional ornithologists, is faster and less harmful than the better known laparotomy. Its effects on survival have been assessed only on pet birds. In this study of wild birds, laparoscopy had no significant effect on subsequent survival and body weight. The technique and procedure are described in detail.

## LAPAROSCOPIA EN EL CAMPO COMO TÉCNICA PARA DETERMINAR EL SEXO DE AVES

**Resumen.**—A un total de 304 cuervos (*Corvus corone corone*) se les identificó (tanto en el campo como en el laboratorio) su sexo utilizándose la técnica del laparoscopia. Se utilizó un artroscopio de Hopkins para observar la gónada de las aves. La técnica de laparoscopia es más rápida y segura que el método de laparotomía que es más ampliamente conocido por los ornitólogos. En este estudio con aves silvestres se encontró que la inspección (examen) laparoscópica no tiene efecto significativo en la subsecuente supervivencia y peso de las aves intervenidas.

In this paper I describe laparoscopy for sex determination of monomorphic birds, and assess its effects on Carrion Crows (*Corvus corone corone*) in the wild. Laparoscopy uses an optical telescope and may be an alternative to the better known laparotomy.

The classical method for sex determination in sexually monomorphic birds is laparotomy. A lateral incision is made parallel to the posterior ribs, the ribs are forced apart, and the gonads are viewed. This method requires an incision of considerable length and probing for the gonads may be harmful to the internal organs and lead to death by internal bleeding (Berthold 1969). Rohwer (1975) observed post-operative limping for several days and higher attack rates by conspecifics. Berthold (1969) reported reduced locomotor activity and weight loss over the first ten days after operation. Only a few studies (e.g., Ketterson and Nolan 1986) assess the effects of laparotomy on survival in the wild, although this information is important for the analysis of population data. Other methods for sexing monomorphic birds include excretory steroid hormone analysis, creatinine determination, and karyotype analysis. They are all described and discussed by Fry (1983). He also gives details on laparoscopy and laparotomy.

Avian laparoscopy is an alternative technique for sex determination. So far it has been used and described mainly by veterinarians and its

effects on survival assessed in pet birds and birds in zoos (Greenwood 1983). These birds, however, live without the daily struggle for food, shelter, social position or defense of a territory which, in wild birds, may increase post-operative weight loss or mortality.

In a study on adult, juvenile, and nestling Carrion Crows, I used a Hopkins arthroscope to determine the sex of 304 individuals in both the laboratory and the field. After the operation the survival and body weights of wild individuals were monitored.

#### METHODS

Endoscopic laparoscopy was performed on both nestlings and older birds. Nestlings were sexed in the field, inside a laboratory-equipped bus. Juvenile and adult birds were caught between November and March in a large crow trap, in Lausanne, Switzerland. The trap was usually emptied at night and the birds were then transferred to an aviary. Since large, full guts may obstruct a clear view of the gonads, most birds were neither fed nor watered until the next morning, when laparoscopy took place in the laboratory. Some birds were processed immediately after capture, and despite the full guts the gonads could be viewed clearly.

The instruments consist of a 30 degree forward-oblique arthroscope 2.7 mm in diameter (Karl Storz, model 27018 BS), connected by an optic fiber cable to a cold light source (model 482 B) which works on 220 volts AC. The total price of the equipment is approximately \$2500. In the field a transformer was used to provide 220 volts off a 12 volt car battery.

Preceding the operation a ketamin-based anesthetic (Imalgène 1000) was injected into the pectoral flight muscle. Anesthetic dosing was 0.35 ml per kg body weight. The bird was then placed on a piece of pre-cut foam which allowed a crow to lie comfortably on its right side (Fig. 1). Both wings were held upwards by an elastic band and the left leg was pulled backwards by a second elastic band, thus freeing access to the postero-lateral part of the rib cage. A Merfen-alcohol solution was used to disinfect the area, as well as all the instruments. A sharp obturator placed inside an endoscope sheath was then introduced between the last and the second-last rib, just below the processus uncinatus. The sheath diameter is 3.8 mm. Once the sheath and obturator had passed the thin intercostal muscle, the obturator was retracted and the arthroscope introduced into the sheath. A look through the arthroscope now gave a view of the intestinal tractus, kidney, lung, airsac and gonads, which lay just posterior of the adrenal body. Even in nestlings it was at this point always immediately clear whether the inspected bird was a male or a female. Arthroscope and sheath were then retracted and the puncture in the skin closed with a single stitch, using medical catgut. A liquid skin adhesive (Skin Spray, Perfecta AG, Bern) was applied over the small area of the puncture. The whole procedure, from the beginning of anesthesia to the application of the liquid skin, averaged less than 3 min. The bird woke up after ten minutes and was then aged, measured, ringed, and wing-

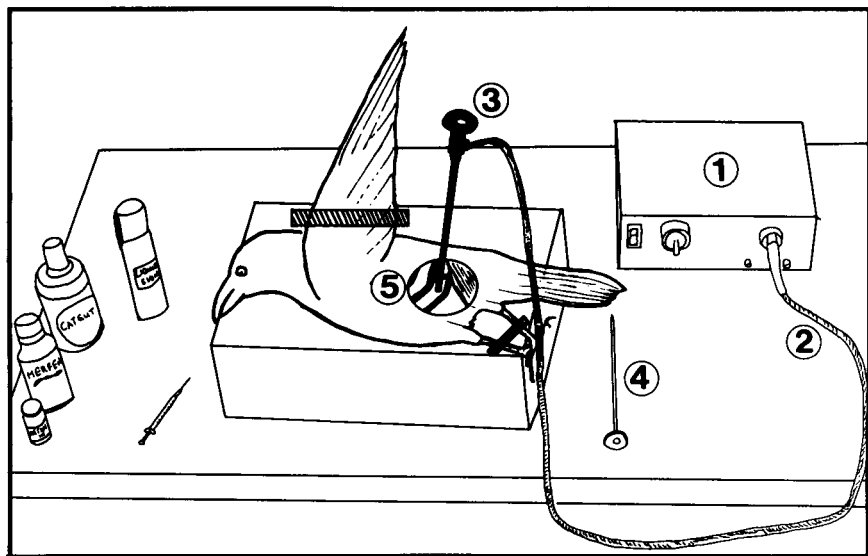


FIGURE 1. Equipment for performing laparoscopy: cold light fountain (1), fiber optic light cable (2), Hopkins arthroscope inside sheath (3), sharp obturator (4). External view of the inspection site with the sartorius muscle to the right and the two posterior ribs with the arthroscope introduced just below the processus uncinatus of the second-last rib (5).

tagged. Many of the sexed birds were recaptured the following days and weeks. On recapture a bird was weighed and the place where the arthroscope had been introduced was inspected.

## RESULTS

*Juvenile and adult birds.*—The laparoscopy technique was used to determine the sex of 245 juvenile and adult Carrion Crows between January 1987 and February 1988. Following initial capture, 51 birds were recaptured 3–20 d later, and weighed. Pairwise comparison of weights at sexing and recapture showed no significant change (pairwise *t*-test,  $t = 0.67$ ,  $df = 50$ ,  $P = 0.51$ ). Twenty-five birds were on average ( $\pm 1$  SD)  $7.4 \pm 4.5$  g heavier at recapture, and 21 birds were on average  $7.0 \pm 3.9$  g lighter (Fig. 2).

In order to assess the effect of laparoscopy on survival, I used a control group of 199 Carrion Crows that were not laparoscoped, captured between March 1985 and December 1986. One hundred and fifteen (47%) of 245 laparoscoped birds were seen 3 mo after the operation, whereas 83 (42%) of 199 control birds were seen 3 mo after their initial capture, not a significant difference (corrected  $\chi^2 = 1.01$ ,  $df = 1$ ,  $P > 0.3$ ). Thus gonad inspection by laparoscopy does not affect survival.

External inspection of recaptured birds showed no sign of infection or

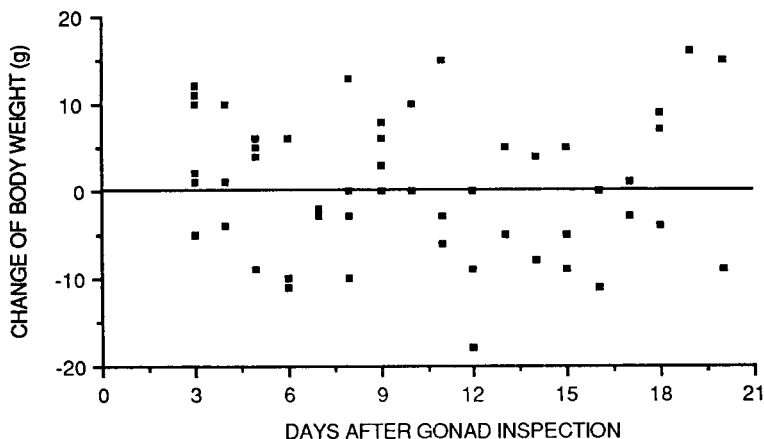


FIGURE 2. Weight changes of 51 juvenile and adult Carrion Crows following laparoscopic gonad inspection.

subcutaneous emphysema as described for laparotomized birds (Fiala 1979, Risser 1971). I performed a second internal inspection on 23 adult and juvenile birds: none of them showed an infection and in three cases where the airsac had been punctured, this hole had also healed.

*Nestlings.*—Fifty-nine nestlings were sexed when weight and size had reached the asymptote of a logistic growth curve. Their fledgling weight varied between 300 and 490 grams. Of these nestlings, 27 were weighed again 1–6 d after the operation and no significant difference between weight at sexing and later weight was observed (pairwise *t*-test,  $t = 0.58$ ,  $df = 26$ ,  $P = 0.57$ ). Fourteen nestlings gained on average  $8.6 \pm 4.7$  g and 12 nestlings lost on average  $7.8 \pm 2.5$  g (Fig. 3).

#### DISCUSSION

Laparoscopy has several advantages over laparotomy. The puncture wound is very small, no probing is required, the operation is quick, and no uncertainty is associated with the sex determination.

Fiala (1979) reports that in the laparotomy it is difficult to avoid puncturing the airsac, which can lead to subcutaneous emphysema. In the case of laparoscopy this can be avoided. The diameter of the arthroscope used here was 2.7 mm, the sheath diameter was 3.8 mm. For smaller birds even thinner arthroscopes with diameters of 1.9 mm and sheath diameters of 2.4 mm, costing about \$3000, are commercially available. General anesthesia may not be necessary, but since no negative effect or mortality attributable to anesthesia was observed, it was thought that the procedure might be less stressful to a bird if anesthetized.

Studies where laparoscopic sex determination was used on captive birds belonging to zoological collections and private breeders reported a mor-

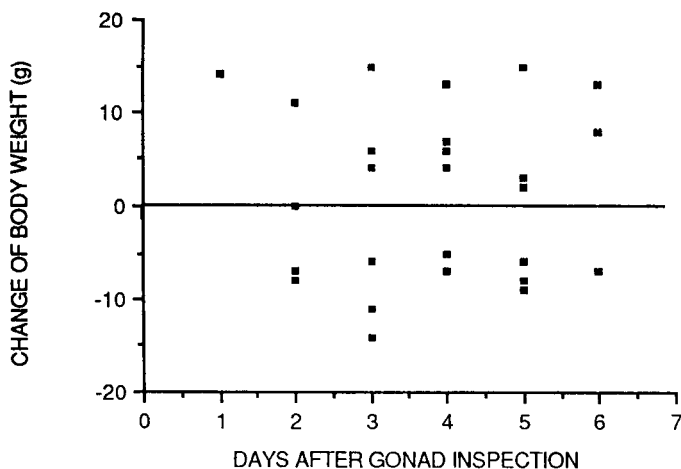


FIGURE 3. Weight changes of 27 fledgling Carrion Crows following laparoscopic gonad inspection.

tality rate below one percent as a direct result of the procedure (Greenwood 1983) and 1.5 percent of these birds could not be confidently sexed for various reasons, e.g., extensive fat deposits around the gonads. In the present study on birds in the wild, there were no negative effects of laparoscopical sexing on body weight or mortality. This may hold true also for the laparotomy technique if properly performed (Ketterson and Nolan 1986). The real advantage of laparoscopy over laparotomy may be rather the greater probability that the gonads will actually be seen and identified once the operation has been performed.

#### ACKNOWLEDGMENTS

I am grateful to Dr. med. vet. Ruedi, Director of the Zoological Garden in Basel, who introduced me to the technique and sexed the first crow. The Swiss general importer of Storz endoscopes, Mr. Anklin in Basel, kindly lent me an arthroscope during one breeding season. I am grateful to E. H. Burtt, Jr. and two referees for their detailed suggestions on the manuscript. I thank Dr. R. K. Furrer and R. Lévêque for their help in a literature search. Finally I thank Prof. P. Vogel for the facilities provided in the Zoology Department, University of Lausanne. Permission for laparoscopic gonad inspection was given by the Service vétérinaire cantonale, Lausanne.

#### LITERATURE CITED

- BERTHOLD, P. 1969. Die Laparotomie bei Voegeln. *Der Zool. Garten* 37:271-279.  
 FIALA, K. L. 1979. A laparotomy technique for nestling birds. *Bird-Banding* 50:366-367.  
 FRY, D. M. 1983. Techniques for sexing monomorphic vultures. Pp. 356-374, in S. Wilbur and J. Jackson, eds. *Vulture biology and management*. University of California Press, Berkeley, California.  
 GREENWOOD, A. G. 1983. Avian sex determination by laparoscopy. *The Vet. Rec.* 112: 105.

- KETTERSON, E. D., AND V. NOLAN, JR. 1986. Effect of laparotomy on Tree Sparrows and Dark-eyed Juncos during winter on subsequent survival in the field. *J. Field Ornithol.* 57:239-240.
- RISSE, A. C. 1971. A technique for performing laparotomy on small birds. *Condor* 73: 376-379.
- ROHWER, S. 1975. The social significance of avian winter plumage variability. *Evolution* 29:593-610.

Received 8 Sep. 1987; accepted 24 Sep. 1988.